

Headache of Extracranial Origin

California Medicine

November 1958, Vol. 89, No. 5, pp. 314-17

Emil Seletz, MD

FROM ABSTRACT:

The cervical spine, usually regarded as a supporting structure for the head, is also an important viaduct of vessels and nerves which must function with little clearance in a congested and moving space bounded by bone.

Pressure in this viaduct is an important cause of headache.

The cervical foramina although apparently roomy, are constricted by cartilage, by the vertebral artery and its adnexae, and by the lateral intervertebral joints. Osteophytosis, swelling or adhesions in this constricted space almost inevitably causes painful vascular or neural disorder.

In certain postures of the neck the vertebral artery is constricted or even occluded.

Traction or sprain may likewise cause headache through disturbance of the vertebral arterial nerves, the posterior cervical autonomic system or the spinal accessory nerves which originate in delicate filaments from all points of the cervical spinal cord.

The migraine-like suboccipital and retro-orbital headache is due to disturbance of the second cervical nerve, which communicates with the first division of the trigeminal nerve.

Headache due apparently to a minor scalp contusion may really be due to irritation of a trigger area at the site of an old scalp injury.

DR. SELETZ ALSO NOTES:

The cervical spine contains "delicate and complex nerves and blood vessels."

"Encroachment within the cervical foramina, irritating the nerve roots, may be due to occupational or disease deformity or to bony overgrowth, but most often it is due to trauma."

Ruth "Jackson [MD] expressed belief that 90% of patients with symptoms of cervical nerve root irritation have had a sprain of the cervical spine at some time. Often the injury is minor and eventually forgotten."

Three fourths of the cervical spine neural foramen is "occupied by structures other than the nerve root, [such as the vertebral artery and its adnexae] and additional space may be occupied by the rarely mentioned lateral intervertebral joint."

At the lateral margins of the cervical disc is a "small synovial joint," first described by Von Luschka in 1858. Other names for these joints of Von Luschka include:

- Covertebral articulations
- Uncovertebral joints
- Neurocentral joints
- Lateral intervertebral joints

"Where the nerve root emerges from the vertebra it is in intimate contact with the lateral intervertebral joint, and is subject to potential irritation with every turn of the head."

"On degenerative thinning of the disc (especially after trauma) the processes of the lateral joints are gradually forced out laterally, causing spurs or osteophytes."

These osteophytes can project laterally, encroaching upon the contents of the intervertebral foramen or foramen transversarium.

Since these osteophytes have a radiotranslucent cartilage cap, the encroachment is always greater than that shown on a standard x-ray.

Another source of nerve root irritation is subsequent to neck sprain "in which hemorrhage into capsular ligaments of the lateral joints, no matter how minute, causes adhesions, as it often does, between the ligaments and the dural sleeve of the nerve roots." **[Important]**

"The author has observed, at operation, severe nerve root swelling and dural adhesions at this point, despite failure to demonstrate the abnormality by roentgenography and electromyography."

"The Vertebral Arterial Nerves and the Posterior Cervical Autonomic System"

In 1925-1928, the syndrome of Barre-Lieou was described. It consists of migraine-like symptoms attributed to disturbance of sympathetic tone about the vertebral artery. Typical symptoms include severe headache, cervical pain, tension headache and occasionally facial neuralgia. There are also reports of diplopia, ataxia, and disturbance in swallowing.

It is documented that Barre-Lieou syndrome can be caused by sprain of the cervical spine.

“The vertebral [sympathetic] nerve originates from the stellate [inferior cervical sympathetic] ganglion and ascends in the transverse foramen, along with the vertebral artery. It supplies the vertebral and basilar arteries—the major blood supply to the pons and medulla, including the area that contains the nuclei of origin of the 5th, 6th, 7th, 8th, 9th, 10th 11th cranial nerves.”
 [I would have added the 12th and not included the 11th]

“The Upper Cervical Nerves”

The spinal accessory nerve (cranial nerve XI) originates from many filaments from the entire length of the cervical spinal cord. “Any acute torsion, flexion, extension or rotation of the neck exerts traction on these delicate filaments, resulting in spasm of the trapezius and sternomastoid muscles.”

“In addition, spasm of the trapezius muscle exerts traction on the greater occipital nerve at the point of where the nerve pierces the tendinous attachment of the upper trapezius muscle,” resulting in occipital pain and headache.

The greater occipital nerve innervates the scalp, the upper part of the neck and portions of the face. The C2 nerve root becomes the greater occipital nerve as it pierces the tendon of the trapezius at the base of the skull.

The C2 nerve root is the most vulnerable to trauma because “it is not protected posteriorly by pedicles and facets.”

Also, cervical trauma causes a “tractional injury” to the C2 nerve root because its exit is between C1 and C2, the point of “greatest rotation of the head on the neck.”

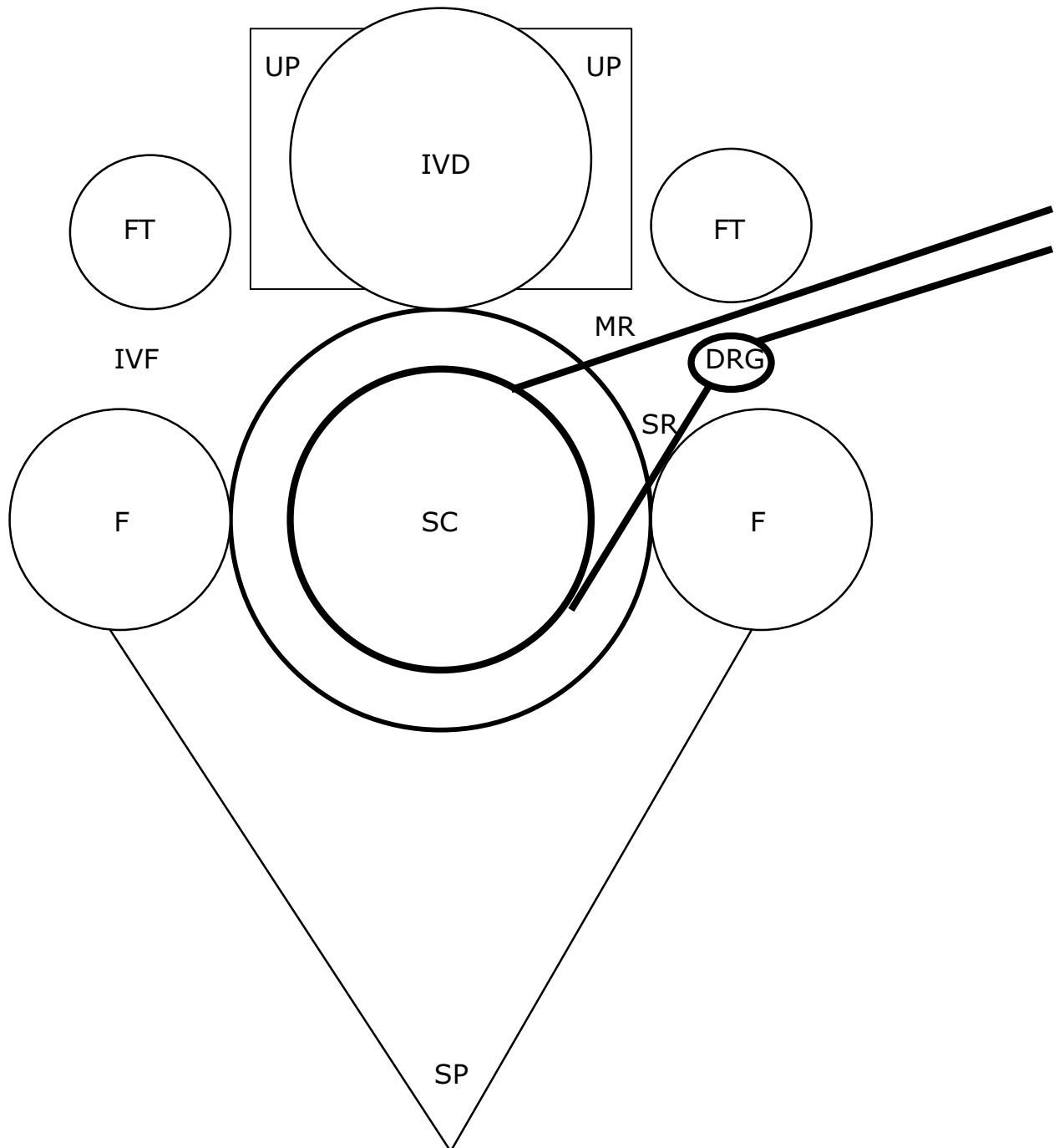
“Occipital-Trigeminal Relations”

There is a communication between the sensory fibers of the greater occipital nerve (C2 nerve root) and the first division (ophthalmic) in the spinal 5th tract of the medulla [trigeminal cervical nucleus]. This gives rise to pain behind the eye. “The patient often feels as if the eyeball is being torn from the socket. The headaches are migraine-like and often associated with nausea, vomiting and blurred vision.” This is the mechanism by which neck sprain can cause hemicrania.

An old scalp contusion [scar tissue] can cause persistent, recurrent, severe headaches. This mechanism of extracranial headache is often overlooked. Treatment is to the [scar].

Cervical Axial View

DRG	= Dorsal Root Ganglion	MR	= Motor Root
F	= Facet	SC	= Spinal Cord
FT	= Foramen Transversarium	SP	= Spinous Process
IVD	= Intervertebral Disc	SR	= Sensory Root
IVF	= Intervertebral Foramina	UP	= Uncinate Process



KEY POINTS FROM DAN MURPHY

- 1) The cervical spine is an important cause of headache.
- 2) The cervical spine intervertebral foramina are constricted by cartilage, by the vertebral artery, and by the lateral intervertebral joints [the uncinat processes]. "Osteophytosis, swelling or adhesions in this constricted space almost inevitably causes painful vascular or neural disorder."
- 3) Sprain or traction injury to the cervical spine may cause headaches by:
 - A)) Causing a disturbance of the vertebral arteries.
 - B)) Causing a disturbance of the plexus of sympathetic nerves that travel along with the vertebral arteries and control their diameter, known as the posterior cervical sympathetic nerves [vertebral nerve].
 - C)) Cause injury to the delicate filaments of the spinal accessory nerves which originate from all points of the cervical spinal cord.
- 4) The C2 nerve root communicates with the first division of the trigeminal nerve (ophthalmic). Greater occipital or C2 irritations can cause "migraine-like suboccipital and retro-orbital headaches."
- 5) The cervical spine contains "delicate and complex nerves and blood vessels."
- 6) "90% of patients with symptoms of cervical nerve root irritation have had a sprain of the cervical spine at some time. Often the injury is minor and eventually forgotten."
- 7) Three fourths of the cervical spine neural foramen is occupied by structures other than the nerve root, such as the vertebral artery and the uncinat process joints.
- 8) At the lateral margins of the cervical disc is a "small synovial joint," the joints of Von Luschka.
- 9) "Where the nerve root emerges from the vertebra it is in intimate contact with the lateral intervertebral joint, and is subject to potential irritation with every turn of the head."
- 10) "On degenerative thinning of the disc (especially after trauma) the processes of the lateral joints are gradually forced out laterally, causing spurs or osteophytes." These osteophytes can encroach upon the contents of the intervertebral foramen or foramen transversarium. Since these osteophytes have a radiotranslucent cartilage cap, the encroachment is always greater than that shown on a standard x-ray.

11) Another source of nerve root irritation is subsequent to neck sprain "in which hemorrhage into capsular ligaments of the lateral joints, no matter how minute, causes adhesions, as it often does, between the ligaments and the dural sleeve of the nerve roots." **[Important]**

12) In 1925-1928, the syndrome of Barre-Lieou was described. It consists of migraine-like symptoms attributed to disturbance of sympathetic tone about the vertebral artery. Typical symptoms include severe headache, cervical pain, tension headache and occasionally facial neuralgia. There are also reports of diplopia, ataxia, and disturbance in swallowing.

13) Barre-Lieou syndrome can be caused by sprain of the cervical spine.

14) The [cervical/upper thoracic] sympathetic nerves that control the flow through the vertebral artery is the major blood supply to the pons and medulla, including the nuclei of origin for cranial nerves 5-12 [maybe not CN eleven].

15) The spinal accessory nerve (cranial nerve XI) originates from many filaments from the entire length of the cervical spinal cord. "Any acute torsion, flexion, extension or rotation of the neck exerts traction on these delicate filaments, resulting in spasm of the trapezius and sternomastoid muscles."

16) Spasm of the trapezius muscle exerts traction on the greater occipital nerve at the point of where the nerve pierces the tendon of the trapezius muscle, resulting in occipital pain and headache.

17) The C2 nerve root is the most vulnerable to trauma because "it is not protected posteriorly by pedicles and facets."

18) Cervical trauma causes a "tractional injury" to the C2 nerve root because its exit is between C1 and C2, the point of "greatest rotation of the head on the neck."

19) The sensory fibers of the greater occipital nerve (C2 nerve root) communicate with the first division (ophthalmic) of the trigeminal nerve in the spinal 5th tract of the medulla [trigeminal cervical nucleus]. This gives rise to pain behind the eye. "The patient often feels as if the eyeball is being torn from the socket. The headaches are migraine-like and often associated with nausea, vomiting and blurred vision." This is the mechanism by which neck sprain can cause hemicrania.

20) An old scalp contusion [scar tissue] can cause persistent, recurrent, severe headaches. This mechanism of extracranial headache is often overlooked. Treatment is to the [scar].